

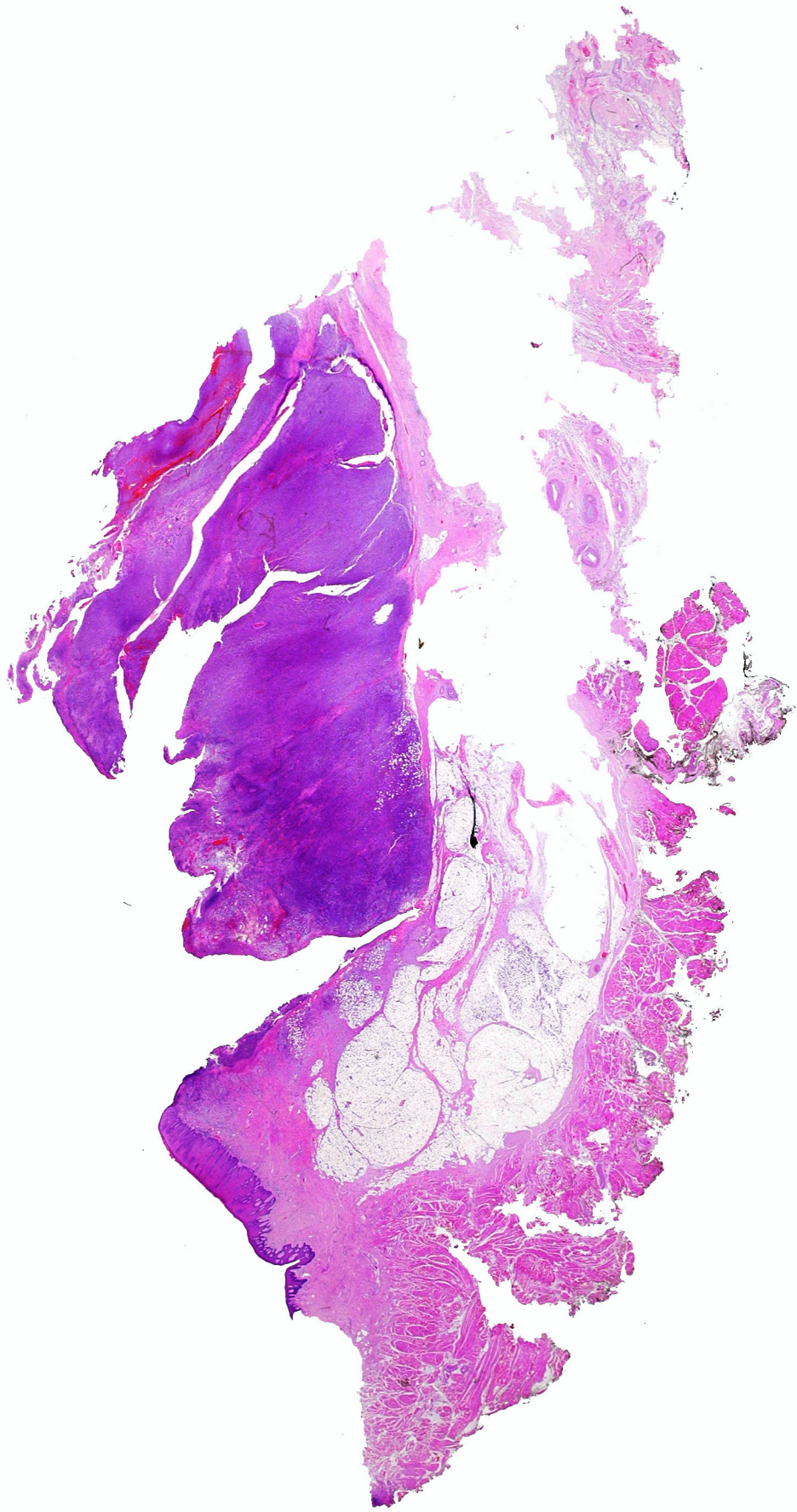Slide Seminar

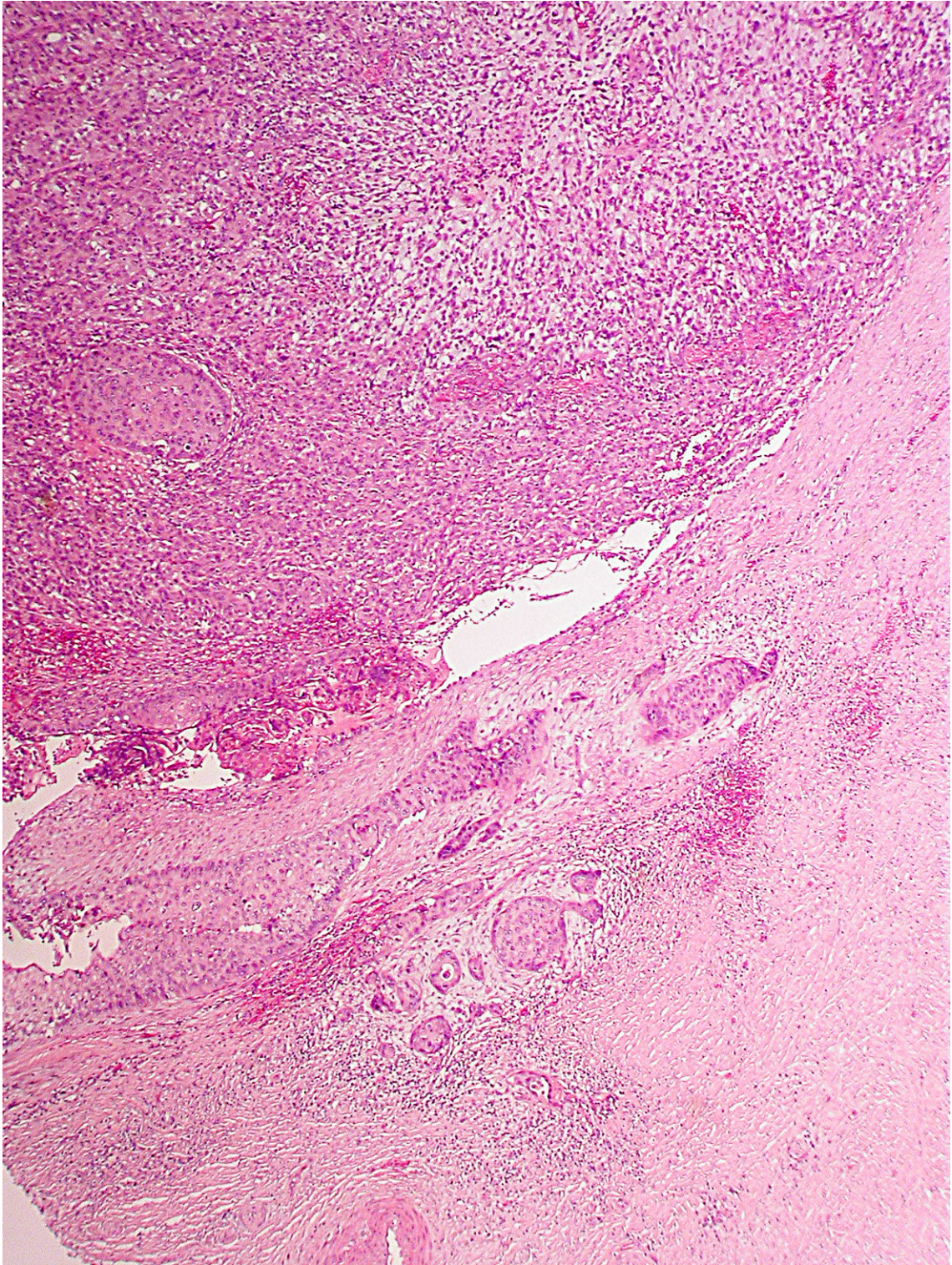
Oral Pathology

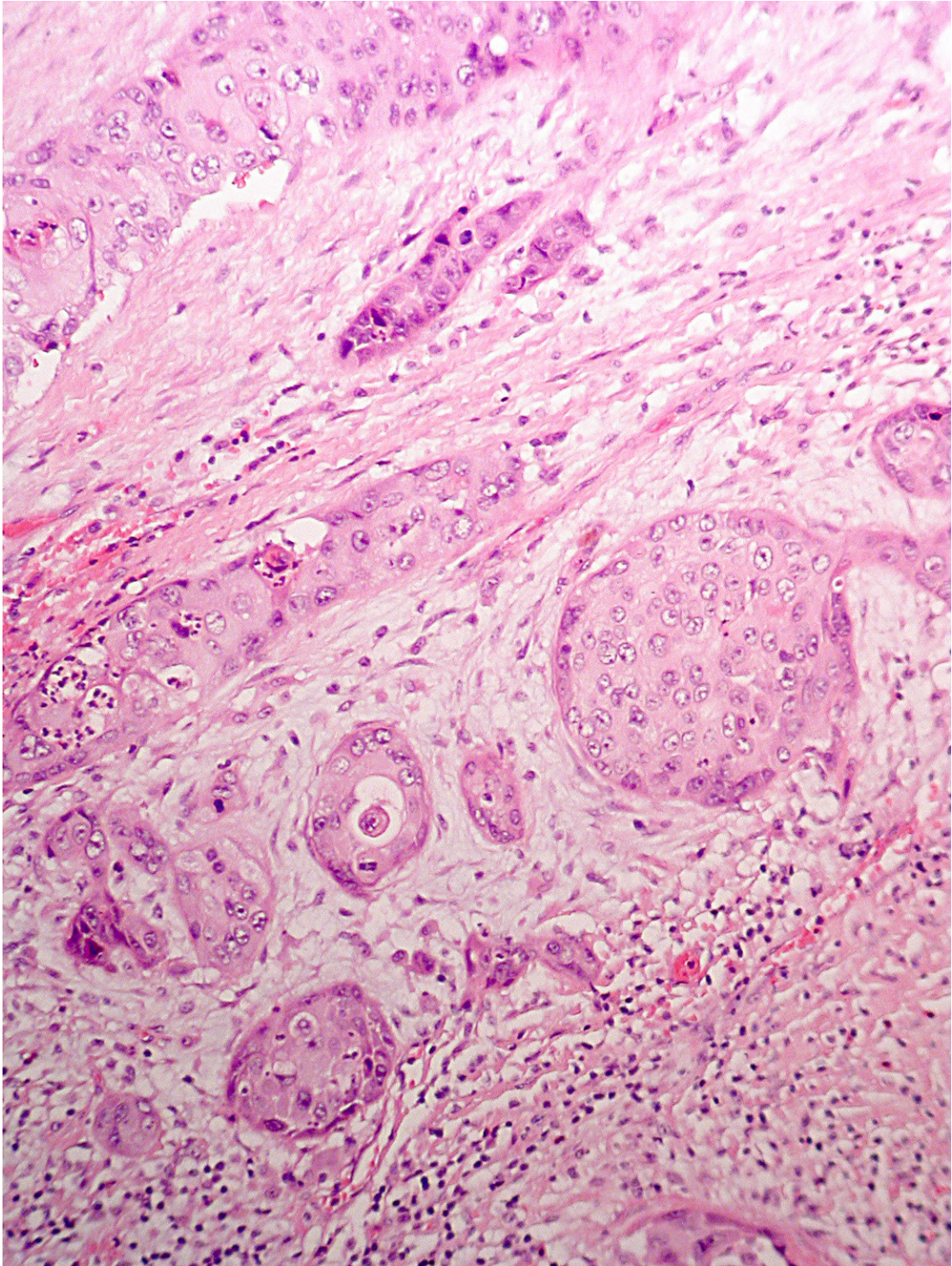
Case 5

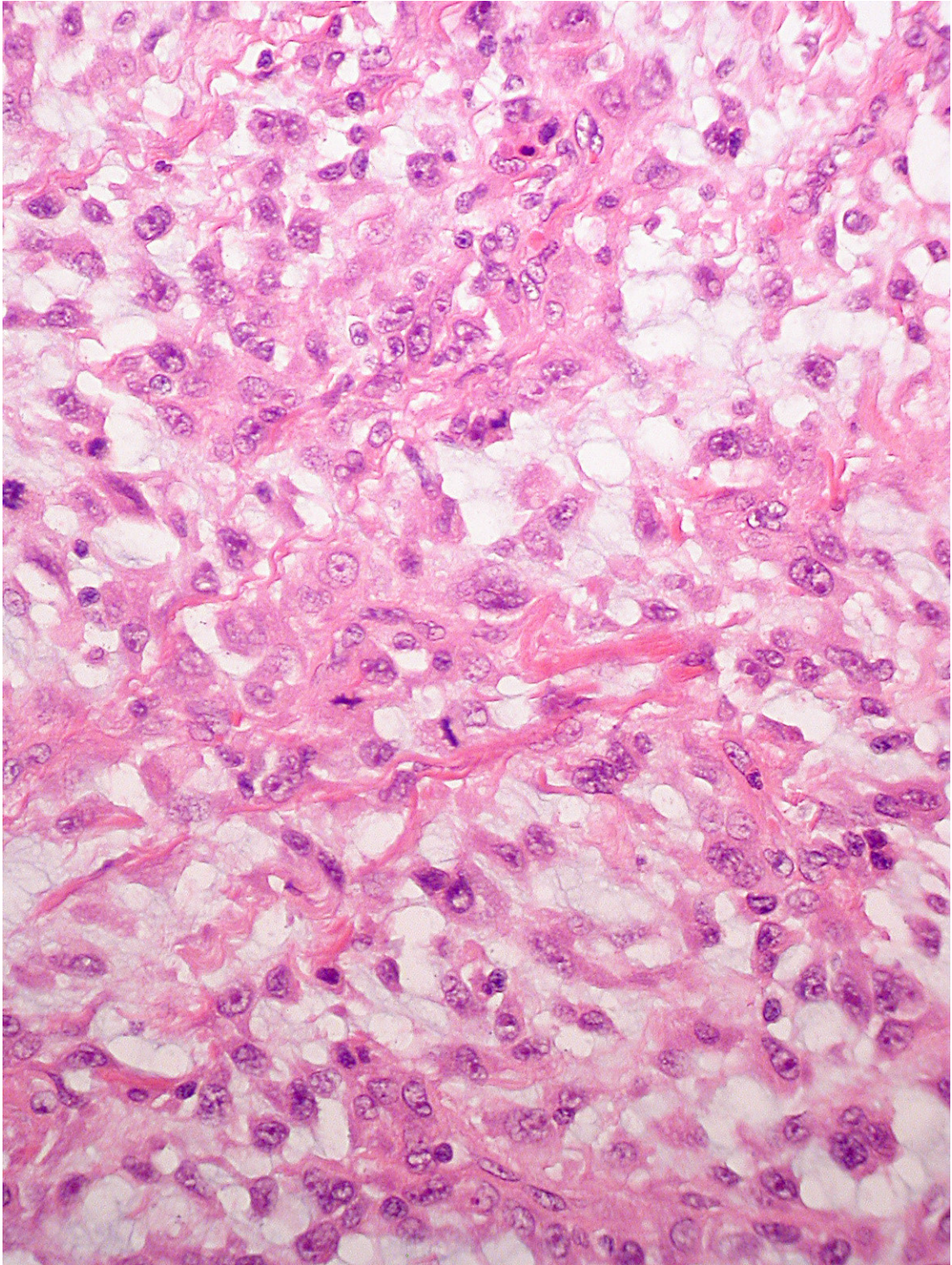
Male 70y

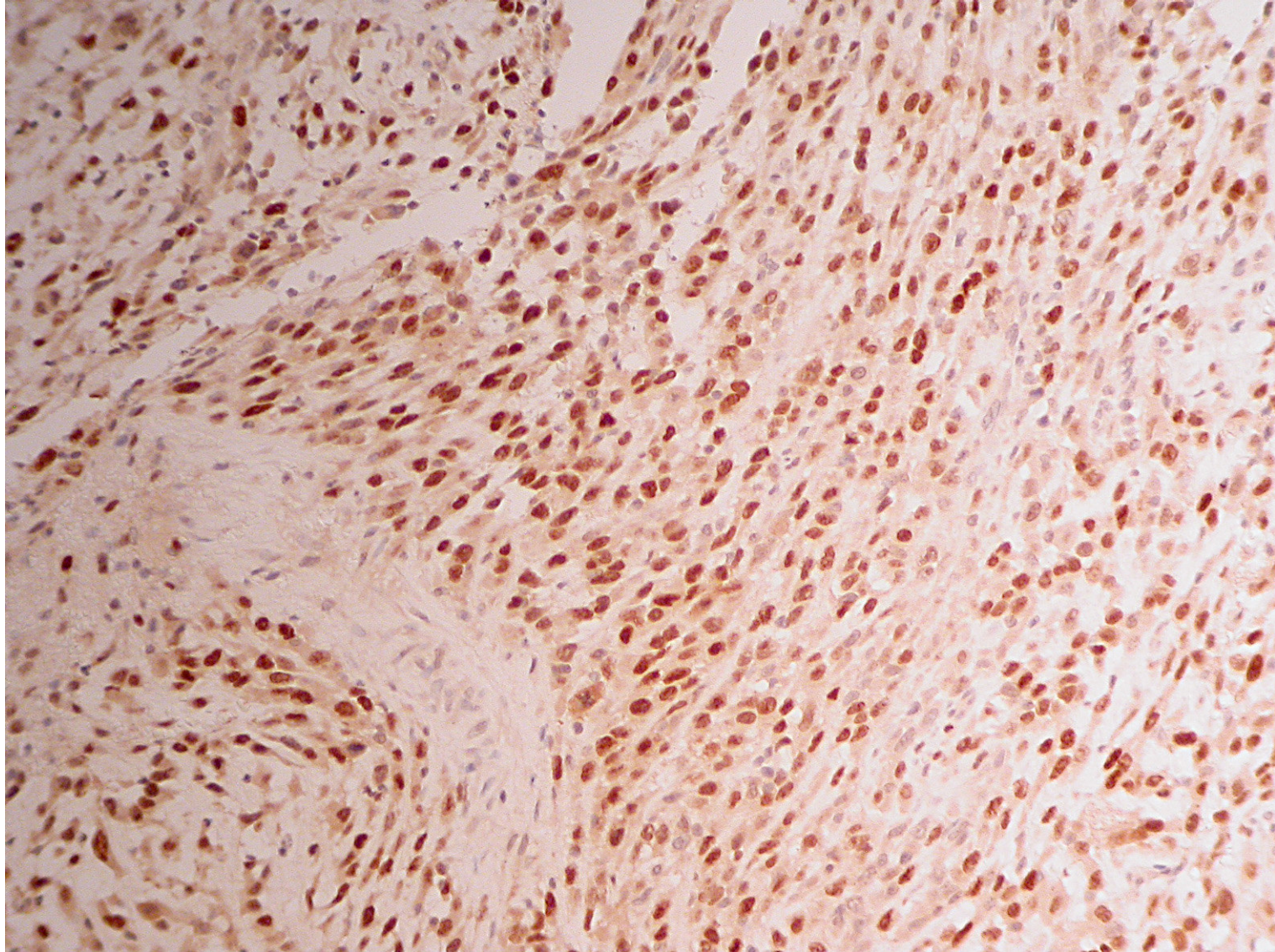
Previous SCC 5 years ago. Large fast growing tumour. Left hemiglossectomy.



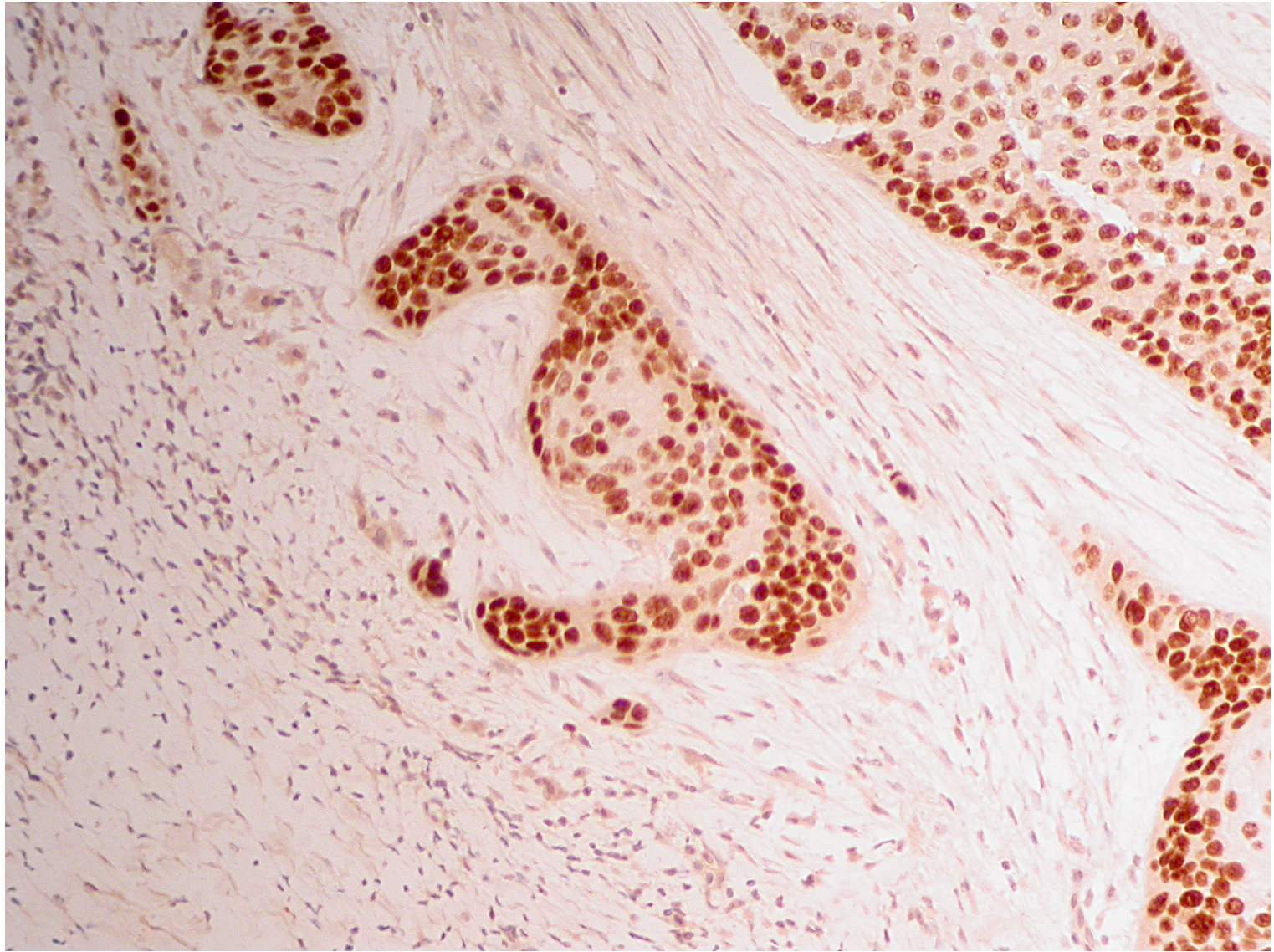




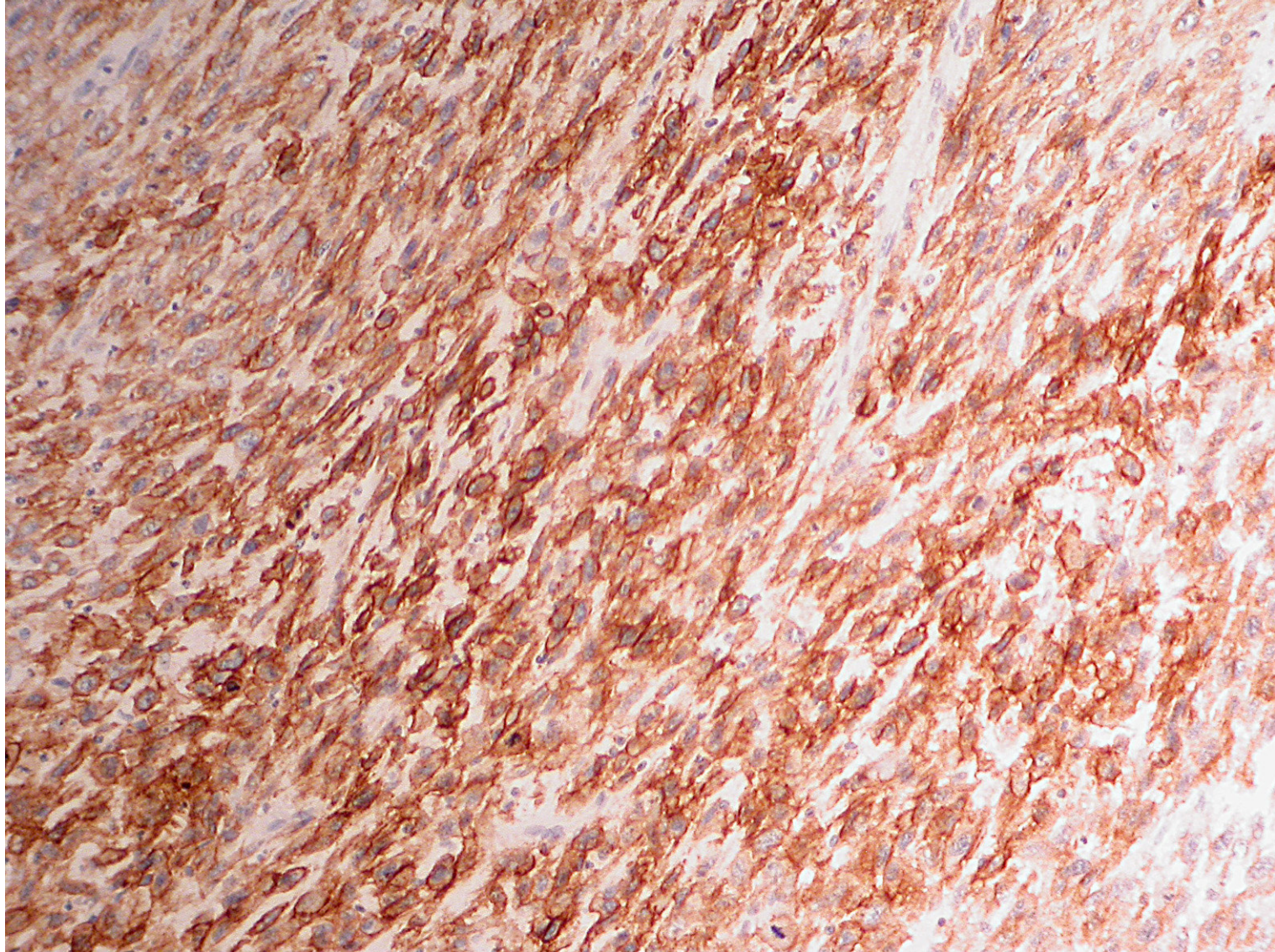




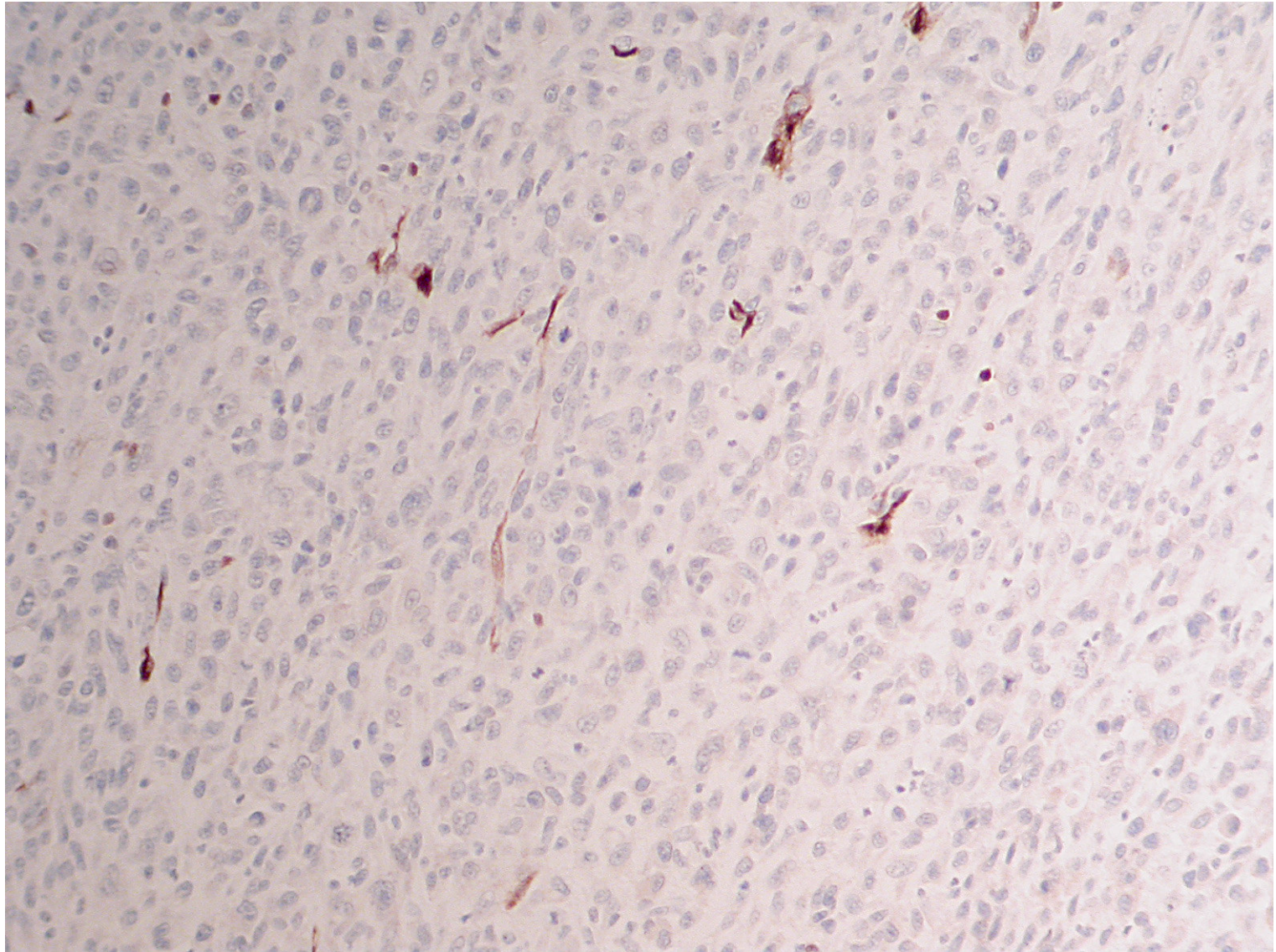
p63



p63



EGFR



p16